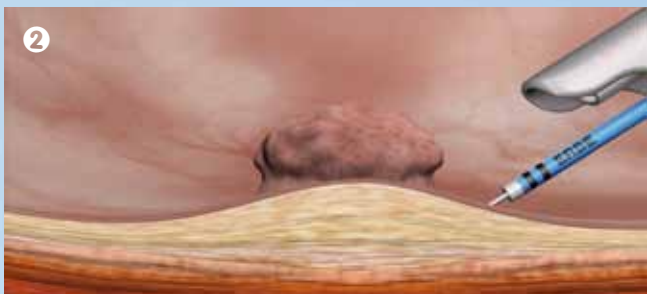
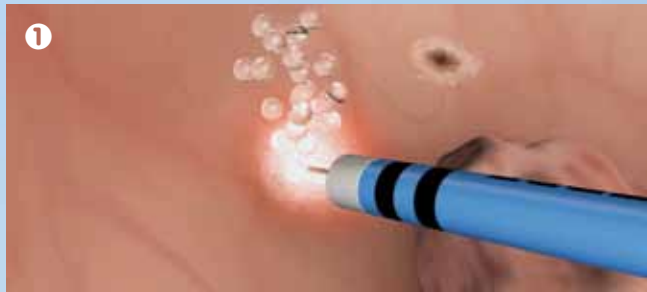

## The 4 working steps with HybridKnife for TUR-B.

### 1 Marking

Prior to elevation, the tumor is marked around in a circle with coagulation points, which also represent the later line of resection. The lateral safety margin to the border of the tumor is about 5–7 mm.

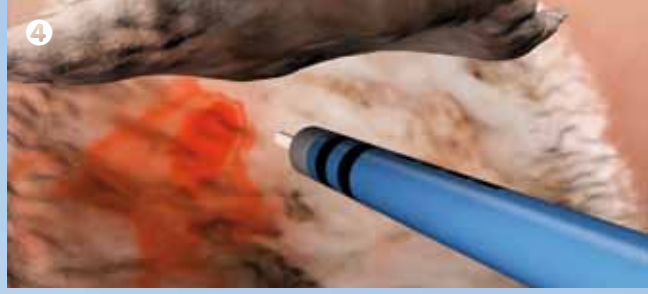
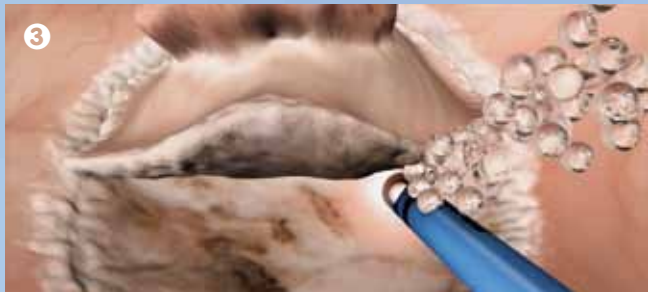

### 2 Elevation

Using the waterjet function, the tumor is elevated by injecting within the marked points. The separation medium accumulates in the submucosa and forms a safety margin to the muscularis. This reduces the risk of perforation during the following resection.

### 3 Incision/Dissection

The tumor is resected after cutting around it at the raised resection level. The modes DRY CUT® or ENDO CUT® Q provide a high-quality cut with optimal hemostasis. Repeating the elevation provides a good presentation of the cut level (beneath the tumor) and contributes towards achieving the desired R0 resection.



### 4 Post-coagulation

Vessels or seeping bleeding occurring during or after the resection can be coagulated with FORCED COAG.

## The HybridKnife models

We recommend these probe types for use in the bladder:

I-Type: Versatile in use, high degree of freedom

T-Type: The model with the best properties for preparing and working under tension, very good coagulation properties


<b>HybridKnife, T-type</b> Ø 2.3 mm; length 1.9 m	<b>No. 20150-060</b>
<b>HybridKnife, I-type</b> Ø 2.3 mm; length 1.9 m	<b>No. 20150-061</b>

## Setting recommendations

Marking	FORCED COAG, Effect 2, 50 Watts
Elevation	E20-30 = 20-30 bar
Incision/ Dissection	DRY CUT, Effect 3, 70 Watts ENDO CUT Q, Effect 2, Cutting duration 4, Interval 4
Coagulation	FORCED COAG, Effect 2, 50 Watts



HybridKnife, T-type  
**No. 20150-060**



HybridKnife, I-type  
**No. 20150-061**

## The Urology Workstation.

**TUR-B with HybridKnife.**  
**And further applications in the urology tract.**

Based on the electrosurgery module VIO® 300 D with the additional modules Waterjet Surgery and Argon Plasma Coagulation, the VIO Urology Workstation is virtually an all-round specialist in the OR. You will find further applications in urology on our web site:

[www.erbe-med.com](http://www.erbe-med.com)



**Urology Workstation**  
VIO® 300 D (Electrosurgery)  
APC® 2 (Argon Plasma Coagulation)  
ERBEJET® 2 (Waterjet Surgery)  
ESM 2 (Aspiration System)  
Bipolar Resection Adapter

## En Bloc Resection of Bladder Tumors using the HybridKnife®

A new method for use in urology

**ERBE**

Perfection for Life

## ESD with HybridKnife A technique is making its mark.

### The advantages of ESD in the gastrointestinal tract (GIT)

The endoscopic submucosal dissection (ESD) is an internationally established technique for the treatment of early carcinomas in the gastrointestinal tract. ESD with HybridKnife is simple and safe, with a steep learning curve. The four work steps, marking, elevation, incision/dissection and coagulation, can be performed without an instrument change.

In this way, non-muscle-invasive tumors and early carcinomas can be resected en bloc with HybridKnife, and with a safe R0 resection border – both laterally and in the downward extension.

Studies by renowned users confirm that\*:

- ✦ Also tumors with a diameter of 20 mm and larger can be resected en bloc with HybridKnife
- ✦ This reduces the rate of recurrence
- ✦ The resection level is raised; the risk of perforation is reduced due to the submucosal elevation layer
- ✦ Accurate histological assessment of the resectate is possible

The waterjet function for elevation of the lesion-bearing mucosa in endoscopy.



### Can the application advantages found in the GIT be transferred to urology?


Past experience with transurethral resection of the bladder, TUR-B, suggest this. Because, like the walls of the organs of the gastrointestinal tract, esophagus, stomach and intestine, the layers of the bladder have a similar structure: mucosa, submucosa and muscularis. The principle of elevation is the same, as also are the further individual steps of the resection of a bladder carcinoma with HybridKnife.

The first hospitals have reported successful interventions on a small number of patients.\*\* For this reason, the new resection method is to be compared with the conventional snare resection method in a wide, multicenter study. Particular attention will be paid to the en bloc resection. The resectates from both techniques will be compared with regard to their pathological evaluation, which has an influence on the further treatment. Also, initial estimates are expected of whether and what positive influence the new method has on the recurrence rate.

The following institutes are taking part in the multicenter study in Germany:

- ✦ University Hospital Dep. of Urology, Tübingen
- ✦ University Hospital Dep. of Urology (LMU), Munich
- ✦ University Hospital Dep. of Urology, Regensburg
- ✦ University Hospital Dep. of Urology, Erlangen

After marking using the electrosurgery function and after elevation, the tumor can be resected and hemorrhages can be coagulated.



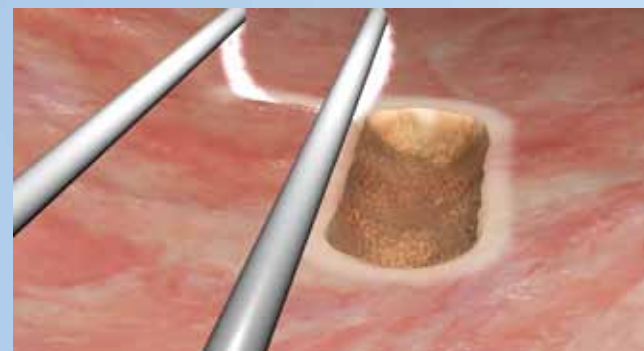
## TUR-B snare resection. Putting the standard to the test.

### Method-dependent risk of recurrence

The conventional transurethral snare resection has up until now been the method of choice for minimally invasive removal and pathological diagnosis of bladder tumors. However, tumors with a diameter greater than 7 mm cannot be resected en bloc. The tumor must be fractionated, which contradicts current oncological recommendations. By cutting up the tumor, it is possible for tumor cells to be released, which can lead to regrowth of the tumor tissue. In addition, breaking up the tissue can make the pathological assessment of the tissue and an exact diagnosis difficult.

All of these criteria are suggestive of putting the gold standard to the test in a comparison with TUR-B performed with HybridKnife.

The method of choice until now: TUR-B with snare. Using the monopolar or bipolar technique.



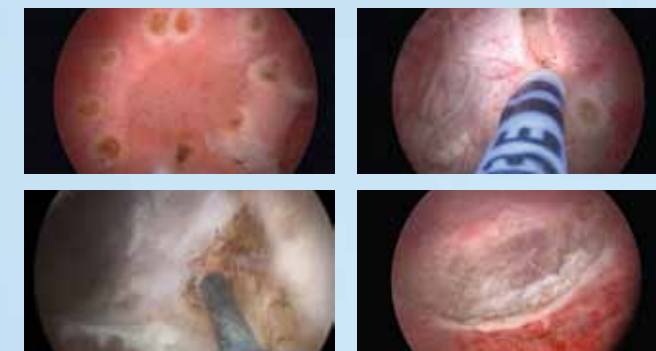
## TUR-B with HybridKnife – A promising alternative?

### The advantages of en bloc resection

The bladder tumor can be resected in one piece using the electrosurgery function of the HybridKnife instrument. By elevating the mucosa, the resection level is raised and the risk of perforation of the muscularis is reduced. The en bloc technique permits a more accurate pathological evaluation after the resection. Complete removal of the tumor can be verified on the basis of a contiguous resection border in the healthy tissue. The prospective, randomized multicenter study will confirm whether the new method has advantages over the gold standard with respect to:

- ✦ improved pathological assessment
- ✦ ability to assess the tumor invasion (lateral and vertical extension of the tumor, R status)
- ✦ improved substaging of T1 tumors
- ✦ initial statements on recurrence and progression rates

En bloc resection of bladder tumors. All individual steps are performed with HybridKnife and without changing instruments.



## References

\* Repici A. et al, High efficacy of endoscopic submucosal dissection for rectal laterally spreading tumors larger than 3 cm, *Gastrointest Endosc* 2013;77:96-101.

Schumacher B. et al, Endoscopic submucosal dissection of early gastric neoplasia with a water-jet assisted Hybrid-Knife: A Western single center's experience, *Gastrointest Endosc* 2012, 75:1166-74.

Schumacher B. et al, Water-jet assisted endoscopic submucosal dissection (ESDH) in comparison to conventional ESD technique for treatment of early gastric cancer, *Gastrointest Endosc* 2012, DDW abstract accepted

Neuhaus H. et al, First Clinical Trial of Endoscopic Submucosal Resection (ESD) of Early Gastric Neoplasia with a Water-Jet Hybridknife (ESDH), *Gastrointest Endosc* 2009; 69: AB259.

Neuhaus H. et al, Endoscopic Submucosal Resection (ESD) of Early Barrett's Neoplasia (EBN) With a Water-Jet HybridKnife (ESDH): First Prospective Clinical Trial, *Gastrointest Endosc* 2010; 71: AB125.

\*\* Fritsche HM. et al, Water-jet-aided transurethral dissection of urothelial carcinoma: a prospective clinical study; *J Endourol.* 2011 Oct;25(10):1599-603. doi: 10.1089/end.2011.0042. Epub 2011 Aug 4

Nagele U. et al, Waterjet hydrodissection: first experiences and short-term outcomes of a novel approach to bladder tumor resection; *World J Urol.* 2011 Aug;29(4):423-7. doi: 10.1007/s00345-011-0653-8. Epub 2011 Feb 9.



The direct link to the publications and the study protocol

**ERBE Elektromedizin GmbH**  
Waldhoernlestrasse 17  
72072 Tuebingen  
Germany  
Phone +49 7071 755-0  
Fax +49 7071 755-179  
info@erbe-med.com  
www.erbe-med.com

**ERBE**

Perfection for Life